

THE ASSOCIATION BETWEEN VERRUCA VULGARIS AND VITAMIN D: IS THERE A CASUAL LINK?

COŞKUN ÖZTEKİN¹, AYNURE ÖZTEKİN², KENAN TAŞTAN³, GÜLSEN GÜL ÖZMEN⁴, SUZAN DEMİR PEKTAŞ⁵

¹MD, Assistant Professor, Department of Family Medicine, Hitit University Medical School, Çorum, Turkey - ²MD, Assistant Professor, Department of Dermatology, Hitit University Medical School, Çorum, Turkey - ³MD, Assistant Professor, Department of Family Medicine, Atatürk University Medical School, Erzurum, Turkey - ⁴MD, Ali Osman Sönmez Onkology State Hospital, Department of Biochemistry, Bursa, Turkey - ⁵MD, Assistant Professor, Department of Dermatology, Muğla Sıtkı Koçman University Medical School, Muğla, Turkey

ABSTRACT

Introduction: Verruca vulgaris is a well-known skin lesion caused by human papillomavirus. There are topical, local invasion and immune therapy options for verruca vulgaris. The role of vitamin D levels in patients with verruca vulgaris is not clear. We investigated the serum vitamin D levels in patients with verruca vulgaris.

Materials and methods: Fifty-five patients with verruca vulgaris (Group I) and 60 healthy controls (Group II) included in the study. The characteristics of verruca vulgaris (duration, clinical type, the number of lesions, family history) and demographics of the participants were recorded. Serum 25-hydroxycholecalciferol levels were measured using electrochemiluminescence binding method.

Results: After covariance analysis, we found no statistically significant difference between the groups in terms of mean age (23.38±4.68 years in Group I versus 27.35±8.14 years in Group II). Other baseline characteristics were not significantly different between the groups ($p > 0.05$ for all). The mean duration of verruca vulgaris was 12 (4-18) years and the most common sites were hand (26 patients, 47.3%) and foot (23 patients, 41.8%). Serum vitamin D levels were 8.35±6.03 ng/ml in Group I and 18.08±10.01 ng/ml in Group II. There was a statistically significant difference between the groups in terms of serum vitamin D levels ($p < 0.001$).

Conclusion: In this study, vitamin D levels in patients with verruca vulgaris were found to be decreased compared to healthy controls. Low vitamin D levels may play an etiological role in the development of verruca vulgaris.

Keywords: Verruca Vulgaris, Vitamin D, Human Papilloma Virus, Serum.

DOI: 10.19193/0393-6384_2018_4_160

Received December 30, 2017; Accepted February 20, 2018

Introduction

Verruca vulgaris (warts) is a common dermatologic disease caused by human papillomavirus (HPV). Most people experience warts at least in one form at some time in their lives. It is transmitted through direct contact with the infected people or contaminated materials and surfaces. Infection is also associated with anatomical site, the amount of infectious virus, trauma, duration of contact, and HPV specific immune status⁽¹⁾.

Several studies highlighted the importance of the expression of antimicrobial peptides working as a defense mechanism against verruca vulgaris⁽²⁻⁴⁾. LL-37 is a peptide belonging to the cathelicidin

family of antimicrobial peptides and is induced within the epidermis during the development of verruca vulgaris⁽²⁾. Human beta-defensin-2 and 3 are also peptides which exhibits antimicrobial activity and may be responsible from the spontaneous regression in verruca vulgaris⁽³⁾. Vitamin D may induce the expression of some antimicrobial peptides including LL-37^(4,5). Therefore, vitamin D may have a role in the treatment of verruca vulgaris.

Insufficiency of vitamin D have been demonstrated up to 50% of the population worldwide in epidemiological studies⁽⁶⁻⁸⁾. Recently, vitamin D or its derivatives have been recommended as potential therapeutic regimen for a variety of neoplastic,

inflammatory, infectious and immunologic diseases⁽⁹⁾. Recently, Raghukumar et al.⁽¹⁰⁾ reported favorable outcomes with intralesional vitamin D3 injections in the treatment of extragenital recalcitrant warts. However, serum levels of vitamin D in patients with verruca vulgaris has not been investigated so far.

The aim of the present study is to investigate the possible relationship between verruca vulgaris and serum vitamin D levels. Table

Materials and methods

This prospective, cross-sectional, randomized study complied with the tenets of the Declaration of Helsinki and was approved by the Ethical Committee of Atatürk University, Erzurum, Turkey. Written informed consent was obtained from all the participants before the study. This study was conducted in Dermatology Clinic of Palandöken State Hospital, Erzurum, Turkey between December 2016 and February 2017.

A total of 55 patients with verruca vulgaris (Group I) and 60 healthy controls (Group II) were included in the study. Exclusion criteria were as follows: (1) age < 18 years and > 50 years, (2) liver disease, (3) kidney disease, (4) pregnancy and lactation (5) use of vitamin D supplementation last six months before the study. Eligible patients with verruca vulgaris who meet the inclusion criteria were chosen using “random number generator” from the medical records. Participants in the control group consisted of healthy volunteers who had no complaints and systemic disease.

Age, sex, marital status, level of education, place of residence (rural or urban), smoking and alcohol use, drug use, and verruca vulgaris characteristics (duration, clinic type, the number of lesions, family history) were recorded. Diagnosis of verruca vulgaris was based on physical examinations by an experienced dermatologist.

Serum collection

Blood from the forearm vein was collected into 5-ml vacutainer tubes with no anticoagulant. The blood samples were centrifuged (1000 × g, 15 min, 4 °C) to separate serum. Serum was removed and immediately stored at -80 °C until analyzed.

Biochemical measurements

Serum 25-hydroxycholecalciferol measurements were performed using electrochemilumines-

cence binding method (COBAS reagent kit; COBAS e601 analyzer series, Roche Diagnostics, Basel, Switzerland). The results were expressed in ng/dl.

Statistical analysis

All data were entered into a spreadsheet, and statistical analyses were performed using R 3.3.2v (open source). Data are shown as mean ± standard deviation for continuous variables, as median (minimum-maximum) for ordinal variables, and as frequency with percent for categorical variables. To evaluate the level of data normality for continuous variables, the Shapiro-Wilk test was used when $n < 50$ and Kolmogorov Smirnov test was used when $n > 50$. Categorical comparisons were made by chi-square test. Independent sample t test was used for comparing the means of continuous variables.

There was a mean age difference between the groups ($p = 0.002$). Therefore, age corrected covariance analysis was performed to eliminate age-related mixing effects on the results. Study groups and age were defined as “fixed factor” and “covariate” variables, respectively. For more than two independent groups, the Kruskal Wallis test was used for non-normally distributed variables. A Spearman's rho correlation was used to analyze the association between non-normally distributed variables. Correlations between normally distributed variables were analyzed by Pearson's correlation coefficient. A p value of < 0.05 was considered statistically significant.

Results

A total of 55 patients (31 females, 24 males) were included in Group I and 60 healthy individuals in Group II (33 females and 27 males). There was a statistically significant difference between the groups in terms of mean age (23.38 ± 4.68 years in Group I versus 27.35 ± 8.14 years in Group II). Other baseline characteristics including sex, marital status, level of education, and place of residence were not significantly different between the groups ($p > 0.05$ for all). Table 1 summarizes the demographics and baseline characteristics of the groups. Seventeen patients (30.91%) were smoking and 1 patient (1.82%) was using alcohol in Group I. Six patients (10.91%) had a history of drug use in Group I.

The mean duration of verruca vulgaris was 12 (4-18) years. Family history of verruca vulgaris was

evident in 16 patients (29.09). The most common sites for verruca vulgaris was hand (26 patients, 47.3%), foot (23 patients, 41.8%), face (one patient, 1.8%), and other locations (5 patients, 9.1%). The mean number of verruca vulgaris per patient was 3 (1-7).

	Groups		P value
	Group I Verruca Vulgaris (n=55)	Group II Control (n=60)	
Age (years)	23.38±4.68	27.35±8.14	0.002
Sex			
Male	24(43.64)	27(45)	0.883
Female	31(56.36)	33(55)	
Marital status			
Married	17(30.91)	28(46.67)	0.084
Single	38(69.09)	32(53.33)	
Level of education			
Primary school	5(9.4)	15(25)	0.099
Secondary school	5(9.4)	2(3.33)	
High School	16(30.02)	19(31.7)	
University	27(50.9)	24(40)	
Place of residence			
Rural	5(9.09)	5(8.33)	0.885
Urban	50(90.91)	55(91.67)	

Table 1: The demographics and baseline characteristics of the groups.

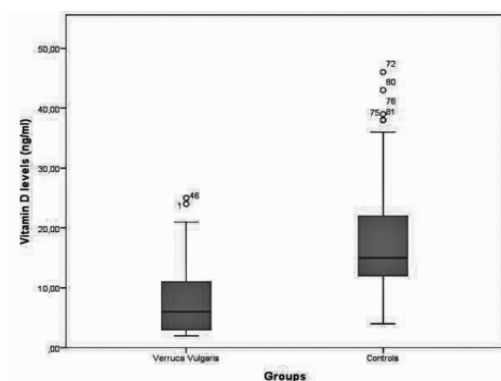


Fig. 1: The mean serum vitamin D concentrations of the groups in a box plot graph.

Serum vitamin D levels were 8.35 ± 6.03 ng/ml in Group I and 18.08 ± 10.01 ng/ml in Group II. There was a statistically significant difference between the groups in terms of serum vitamin D levels ($p < 0.001$). Covariance analysis showed that age did not affect the serum vitamin D levels difference between the groups (Fig.1). shows the mean serum vitamin D concentrations of the groups in a box plot graph.

Discussion

This is the first study evaluating the vitamin D levels in the serum of patients with verruca vulgaris. The results demonstrated decreased levels of vitamin D in the serum of patients with verruca vulgaris compared with healthy control subjects. Vitamin D regulates cell proliferation and differentiation via the vitamin D receptor (VDR) which is present in keratinocytes and lymphocytes of the skin⁽¹¹⁾. Although the exact mechanism of action of vitamin D activity against verruca vulgaris remains to be elucidated, it may have protective and/or preventive role.

Vitamin D has an important role in bone mineralization and calcium homeostasis. Recent evidence suggests that it has beneficial pleiotropic effects on both the innate and adaptive immune system^(12,13). Even though numerous studies suggest that vitamin D has beneficial effects on the immune defense and on allergic diseases, the exact mechanisms are not well understood yet.

Vitamin D increases the expression of several antimicrobial peptides including cathelicidin (LL-37). LL-37 is not only an antimicrobial peptide against bacteria, virus and fungi, but also an immune modulator^(14,15). Elenius et al.⁽¹⁵⁾ found that higher Vitamin D and E levels were associated with less allergic disorders in patients undergoing tonsillectomy. Bucak et al.⁽¹⁶⁾ found that lower vitamin D levels are associated with rotaviral diarrhea in children. Recent works highlights vitamin D's potential role in fighting viral infections^(17,18). Bhat et al.⁽¹⁹⁾ reported lower levels of vitamin D in patients with alopecia areata and found significant negative correlation between the levels of serum Vitamin D and severity of alopecia.

Despite there have been many studies on vitamin D in recent years, experience related with HPV and verruca vulgaris are very limited. Labendeira et al.⁽²⁰⁾ reported successful outcome with the use of topical calcipotriol in the treatment of a giant viral wart. A more recent study concluded the role of intralesional vitamin D3 injection in sixty-four patients with recalcitrant warts of varying sizes and duration.

Complete response was seen in 54 of 60 (90%) of the patients. The authors reported the average number of injections required to achieve a complete resolution as 3.66. Aktas et al.⁽¹¹⁾ used intralesional Vitamin D3 for plantar warts. Twenty patients were included in that study, and 7.5 mg of

Vitamin D3 injection was given at monthly intervals for a maximum of 2 sessions. They reported complete clearance in 80% of patients at the end of 8 weeks. In the present study, we found decreased levels of serum vitamin D in patients with verruca vulgaris compared to healthy controls (8.35 ± 6.03 ng/ml versus 18.08 ± 10.01 ng/ml). In the light of these studies, the role of vitamin D in the treatment of HPV infections particularly in verruca vulgaris is an indisputable fact.

Although several studies have reported favorable results with intralesional vitamin D analogs in skin warts, the role of vitamin D insufficiency in the pathogenesis of verruca vulgarism is unknown. Furthermore, it is not known whether elimination of vitamin D deficiency has a role in the treatment of verruca vulgaris. This study basically showed that serum vitamin D levels in verruca vulgaris patients were lower than in healthy individuals. Further studies are needed to clarify the role of vitamin D (whether protective or therapeutic) on HPV skin infections. The main limitation of this study was the mean age difference between the study and control groups. However, covariance analysis eliminated the age-related mixing effects on the results. The second limitation was the relatively small study population which might hinder extrapolation of the results.

In conclusion, this study is the first to demonstrate decreased levels of vitamin D in patients with verruca vulgaris. Decreased vitamin D levels may play an aetiopathogenic role in verruca vulgaris. Further studies with larger sample size are necessary to confirm our results and the potential protective/therapeutic role of vitamin D from verruca vulgaris.

References

- 1) Kranjec C, Doorbar J. Human papillomavirus infection and induction of neoplasia: a matter of fitness. *Curr Opin Virol* 2016; 20: 129-36.
- 2) Conner K, Nern K, Rudisill J, O'Grady T, Gallo RL. The antimicrobial peptide LL-37 is expressed by keratinocytes in condyloma acuminatum and verruca vulgaris. *J Am Acad Dermatol* 2002; 47: 347-50.
- 3) Meyer-Hoffert U, Schwarz T, Schröder JM, Gläser R. Expression of human beta-defensin-2 and -3 in verrucae vulgares and condylomata acuminata. *J Eur Acad Dermatol Venereol* 2008; 22: 1050-4.
- 4) Wang G. Human antimicrobial peptides and proteins. *Pharmaceuticals* 2014; 7: 545-94.
- 5) Wang TT, Nestel FP, Bourdeau V, Nagai Y, Wang Q, et al. Cutting edge: 1,25-dihydroxyvitamin D3 is a direct inducer of antimicrobial peptide gene expression. *J Immunol* 2004; 173: 2909-12.
- 6) Hoseinzadeh E, Taha P, Wei C, Godini H, Ashraf GM, Taghavi M, Miri M. The impact of air pollutants, UV exposure and geographic location on vitamin D deficiency. *Food Chem Toxicol* 2018; 113: 241-54.
- 7) Lucas RM, Gorman S, Black L, Neale RE. Clinical, Research, and Public Health Implications of Poor Measurement of Vitamin D Status. *J AOAC Int* 2017; 100: 1225-29.
- 8) Schramm S, Lahner H, Jöckel KH, Erbel R, Führer D, Moebus S, Heinz Nixdorf Recall Study Group. Impact of season and different vitamin D thresholds on prevalence of vitamin D deficiency in epidemiological cohorts-A note of caution. *Endocrine* 2017; 56: 658-66.
- 9) Caccamo D, Ricca S, Currò M, Ientile R. Health Risks of Hypovitaminosis D: A Review of New Molecular Insights. *Int J Mol Sci.* 2018; 19. doi: 10.3390/ijms19030892
- 10) Raghukumar S, Ravikumar BC, Vinay KN, Suresh MR, Aggarwal A, Yashovardhana DP. Intralesional Vitamin D(3) Injection in the Treatment of Recalcitrant Warts: A Novel Proposition. *J Cutan Med Surg* 2017; 21: 320-4.
- 11) Aktas H, Ergin C, Demir B, Ekiz Ö. Intralesional Vitamin D injection may be an effective treatment option for warts. *J Cutan Med Surg* 2016; 20: 118-22.
- 12) Bikle DD. What is new in vitamin D: 2006-2007. *Curr Opin Rheumatol* 2007; 19: 383-8.
- 13) Beard JA, Bearden A, Striker R. Vitamin D and the anti-viral state. *J Clin Virol* 2011; 50: 194-200.
- 14) Schaubert J, Gallo RL. Antimicrobial peptides and the skin immune defense system. *J Allergy Clin Immunol* 2008; 122: 261-6.
- 15) Elenius V, Palomares O, Waris M, Turunen R, Puhakka T, Rückert B. The relationship of serum vitamins A, D, E and LL-37 levels with allergic status, tonsillar virus detection and immuneresponse. *PLoS One* 2017; 12 e0172350.
- 16) Bucak IH, Ozturk AB, Almis H, Cevik MÖ, Tekin M, et al. Is there a relationship between low vitamin D and rotaviral diarrhea? *Pediatr Int* 2016; 58: 270-3.
- 17) Hansdottir S, Monick MM, Hinde SL, Lohan N, Look DC, Hunninghake GW. Respiratory epithelial cells convert inactive vitamin D to its active form: potential effects on host defense. *J Immunol* 2008; 181: 7090-9.
- 18) Hansdottir S, Monick MM, Lohan N, Powers L, Gerke A, Hunninghake GW. Vitamin D decreases respiratory syncytial virus induction of NF-κB chemokines and cytokines in airway epithelium while maintaining the antiviral state. *J Immunol* 2010; 184: 965-74.
- 19) Bhat YJ, Latif I, Malik R, Hassan I, Sheikh G, et al. Vitamin D Level in Alopecia Areata. *Indian J Dermatol* 2017; 62: 407-10.
- 20) Labandeira J, Vázquez-Blanco M, Paredes C, Suárez-Penaranda JM, Toribio J. Efficacy of topical calcipotriol in the treatment of a giant viral wart. *Pediatr Dermatol* 2005; 22: 375-6.

Corresponding author
COŞKUN ÖZTEKİN, MD
Department of Family Medicine
Hitit University Medical School
Çorum
(Turkey)